acumed®

The Most Complete Selection of Trimalleolar Fracture Treatment Options on the Market*

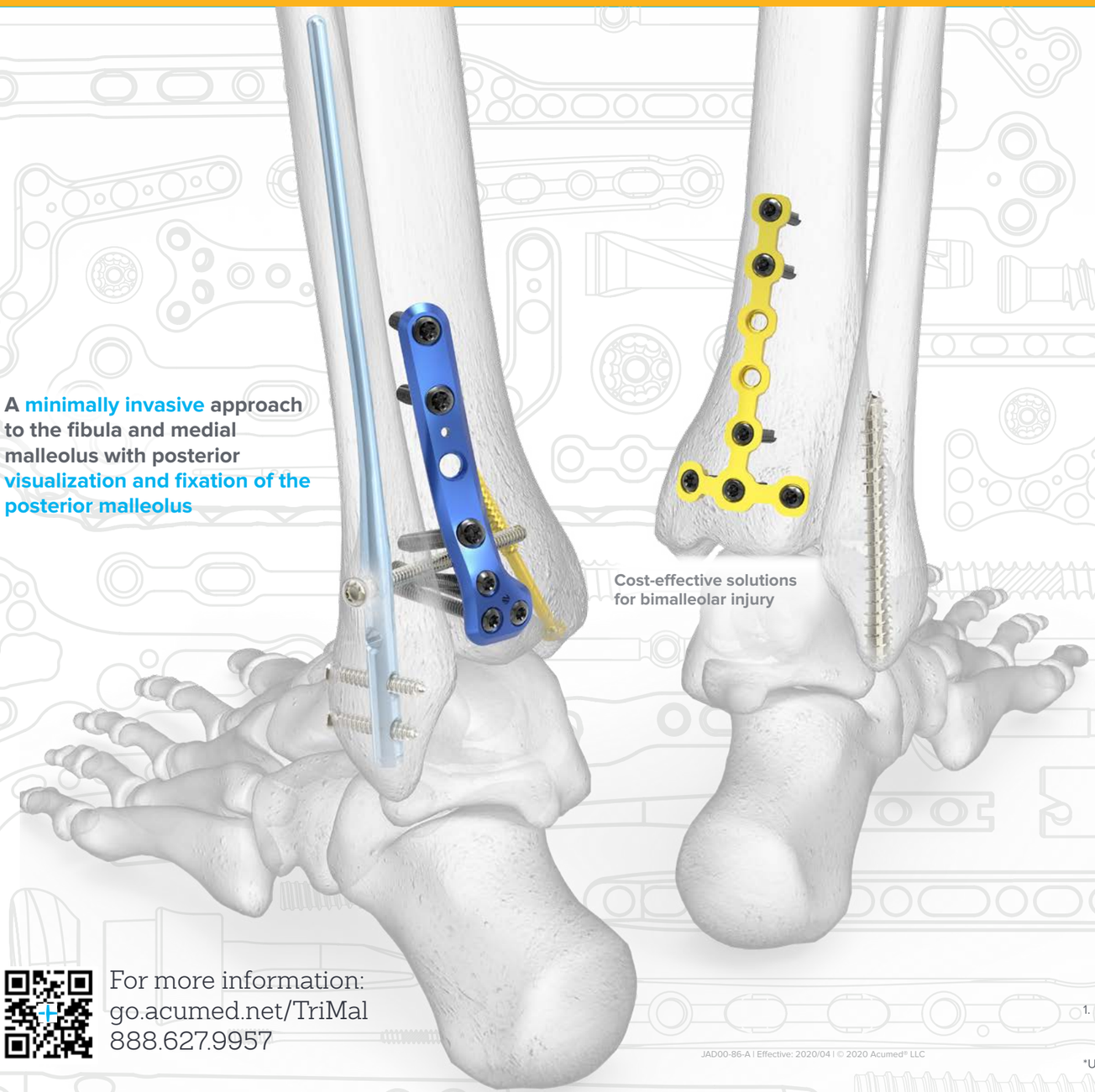

A **minimally invasive** approach to the fibula and medial malleolus with posterior **visualization and fixation of the posterior malleolus**

Cost-effective solutions for bimalleolar injury

Direct fixation of the posterior malleolus achieved syndesmotic stability in 97.9% of patients with trimalleolar or trimalleolar equivalent fractures[1]

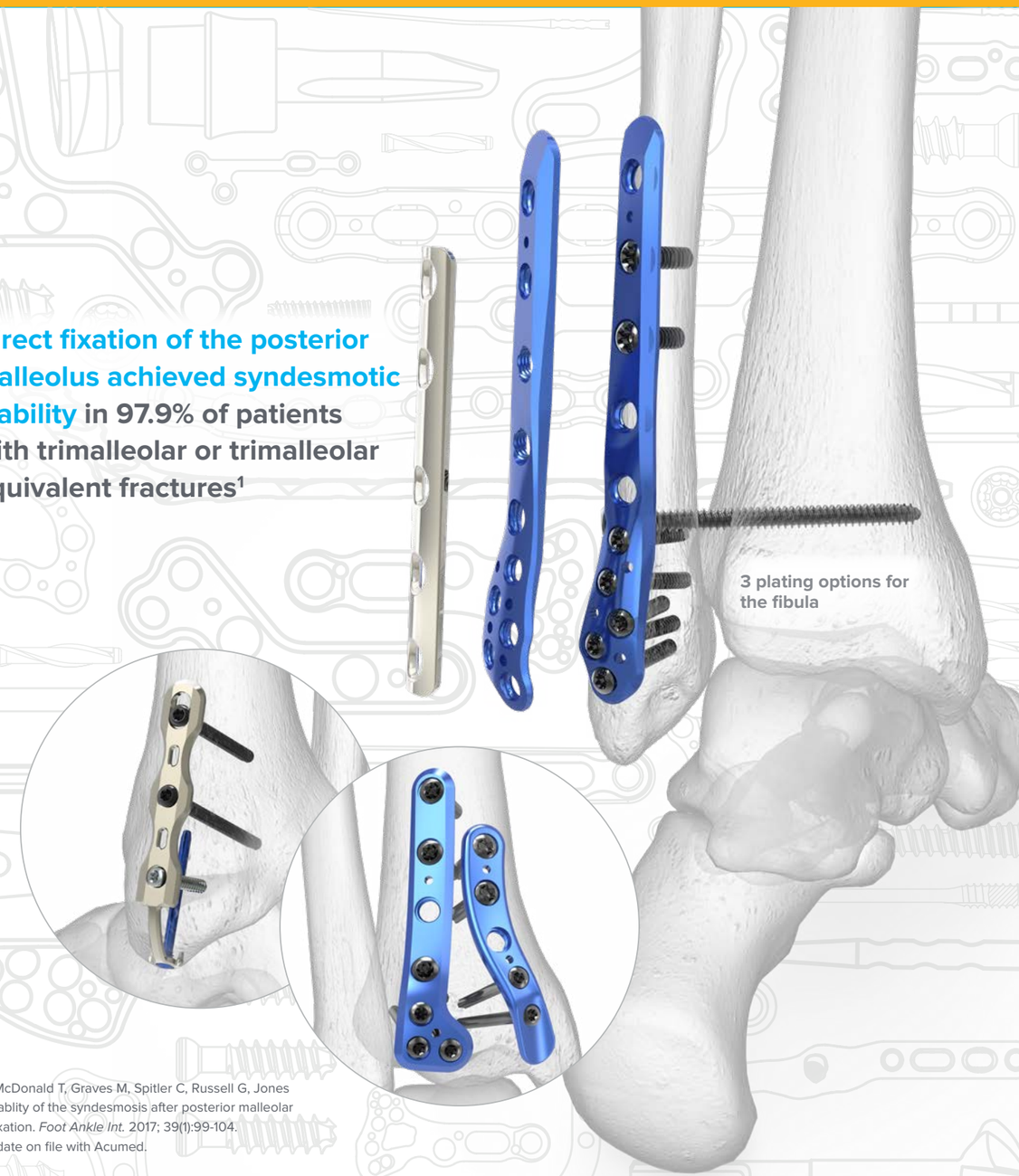

3 plating options for the fibula

For more information:
go.acumed.net/TriMal
888.627.9957

JAD00-86-A | Effective: 2020/04 | © 2020 Acumed® LLC

1. Miller M, McDonald T, Graves M, Spitler C, Russell G, Jones L, et al. Stablity of the syndesmosis after posterior malleolar fracture fixation. *Foot Ankle Int.* 2017; 39(1):99-104.

*US market; date on file with Acumed.